



Report

Magnetic resonance imaging in comparison to clinical palpation in assessing the response of breast cancer to epirubicin primary chemotherapy

Maria Bodini¹, Alfredo Berruti², Alberto Bottini¹, Giovanni Allevi¹, Carla Fiorentino¹, Maria Pia Brizzi², Alessandra Bersiga¹, Daniele Generali¹, Davide Volpi¹, Ugo Marini¹, Sergio Aguggini¹, Marco Tampellini², Palmiro Alquati¹, Lucio Olivetti¹, and Luigi Dogliotti²

¹Radiologia, Breast Unit and Anatomia Patologica, Azienda Ospedaliera Istituti Ospitalieri, Cremona;

²Dipartimento di Scienze Cliniche e Biologiche Università di Torino, Oncologia Medica, Azienda Ospedaliera San Luigi, Orbassano, Italy

Key words: breast cancer, clinical palpation, magnetic resonance imaging, primary chemotherapy

Summary

Purpose. To investigate whether magnetic resonance imaging (MRI) is superior to clinical palpation in the assessment of response of breast cancer to primary chemotherapy (PC).

Patients and methods. Seventy-three patients with T2–4, N0, M0 breast cancer were treated with 3–4 cycles of single agent epirubicin before definitive surgery. MRI was performed at baseline condition and at the end of chemotherapy.

Results. According to the WHO criteria, 20 (27.4%) patients attained a complete response (CR) by clinical palpation and 41 (56.2%) a partial response. The corresponding response rate by MRI was 11 (15.1%) and 34 (46.6%), respectively. Residual tumor assessed by MRI better correlated with pathologic measurements (Spearman r : 0.72) than residual tumor assessed by clinical palpation (Spearman r : 0.58). Post-chemotherapy histology evaluation revealed pathologic CR in three cases, only one of them was considered as complete responder by MRI. Residual disease consisted in *in situ* carcinoma in four cases, one of them was complete responder at MRI, the remaining three showed residual abnormal contrast enhancement indistinguishable from that of invasive tumors.

Conclusions. As compared to pathology specimens, MRI is able to represent the extent of cancer more accurately than clinical palpation. It constitutes a promising technique in assessing the BC response to PC. The current limit of MRI is the scarce specificity in predicting the nature of residual disease.

Introduction

Primary chemotherapy (PC) is now adopted by an increasing number of clinicians as a part of the multidisciplinary approach of either operable or locally advanced breast cancers. Historically this treatment modality was undertaken with the aim of shrinking the tumors and permitting the conservation of the breast [1, 2]. Today, PC is viewed as a means of testing the activity of a therapeutic approach in determining the disease outcome, since it allows a perfect quantifiable evaluation of the chemosensitivity or chemoresistance

of any treated case [2–8]. When compared to adjuvant chemotherapy, results are available quickly, and valuable information can be gathered from proof-of-concept studies involving a relatively small number of patients [6].

Trials of PC have indicated that patients whose primary tumor respond to treatment have a better survival than those who do not respond [1–8]. This finding suggests that it may be possible to use breast tumor response as an indicator of the response of micrometastases to the therapy. Since response could be a potential surrogate parameter of treatment

efficacy, the accurate assessment of tumor shrinkage is crucial.

Clinical palpation is a widely recognized technique for tumor size monitoring during PC [1, 2]. This technique, however, needs experienced clinicians and appears to be inadequate in the assessment of complete response (CR). Measurement of the tumor size is unreliable when the tumor is irregular or diffuse because margins cannot be delineated precisely and the same problem arises if the tumor edge becomes soft as it regresses. Thickening of the overlying skin or subcutaneous tissue may add to this problem. Residual fibrosis can be misinterpreted as an incomplete response while necrosis can actually cause enlargement at the time when the active tumor is shrinking [9].

Imaging techniques may potentially give more objective findings than clinical examination as they could detect changes either in size or density of the tumor mass [10]. Moreover, in case of the patient inclusion in a clinical trial, the imaging results may be evaluable by extramural reviewers.

Mammography and echography have greatly improved the preoperative staging of breast cancer, both techniques have been found to be superior over clinical palpation in finding tumors at an early clinical stage and this has been contributed to reduce the mortality [11].

In our recently published experience involving 145 consecutive cases, however, both mammography and echography were found to be less sensitive than clinical palpation in assessing the changes in breast tumor size after chemotherapy [12]. Tumor dimensions evaluated clinically at the end of chemotherapy showed a better relationship with the tumor size assessed by the pathologist than the measurements performed by both imaging techniques. The greater reliability of response assessed clinically was further supported by the finding that response evaluated by clinical palpation significantly correlated with the disease free survival status, while response assessed by either mammography or echography failed to show any relationship with the disease free survival [12].

On the basis of this experience, we concluded that physical examination still remains the method of choice in evaluating preoperatively the disease response to PC. The diagnostic accuracy of clinical palpation is not improved by echography and mammography [12].

It is generally accepted that contrast magnetic resonance imaging (MRI) is an emerging technology that may revolutionize our management of women

with breast cancer [13–15]. This technique is very sensitive, being able to detect tumors as small as a few millimeters in size [13–15]. The rationale behind the use of MRI also lies in its ability to detect vascularity [15, 16]. Neoplastic tissue uptakes contrast medium earlier and more intensively than normal tissue. The possibility of detecting this enhancement and plotting intensity–time curves that are characteristic of the neoplastic tissue permits MRI to potentially distinguish between benign and malignant breast lesions and between neoplastic tissue and fibrotic tissue. The aim of this study was to evaluate the diagnostic advantages of MRI versus clinical palpation in the assessment of tumor response after PC in human breast cancer.

Patients and methods

Between January 1998 and August 2001, 73 patients with an operable breast tumor or locally advanced disease (T2–4, N0–1, M0) accepted to perform MRI before and after PC in addition to routine diagnostic procedures. Pre-treatment patient demography is outlined in Table 1. None of the patients had objective skin inflammation or edema.

On first presentation an incision biopsy was performed on each patient. Initial staging comprised clinical examination, bilateral mammography, echography, chest x-ray, liver echography or CT scan, bone scintigraphy. Mammography, echography and MRI were performed before incisional biopsy, whereas the other diagnostic procedures were done afterwards.

Treatment

Chemotherapy was started within 1 or 2 days of diagnosis. All patients were treated with single agent epirubicin (120 mg/m² divided in two doses administered on days 1, 2 every 21). Three or four chemotherapy cycles were administered.

The size of primary tumor was carefully measured every cycle by palpation by the same clinician using a caliper. In order to avoid interference due to post-biopsy edema, tumor shrinkage was evaluated from the second course onwards. The tumor size measurements with MRI, at baseline and before surgery, were independently reviewed by two experienced radiologists specialized in breast imaging. Any discrepant readings were resolved by consensus. The post-treatment MR images were assessed for the presence of any abnormality that might indicate potential

Table 1. Patient characteristics

Number of patients	73
Median age (range)	56 (26–71)
Primary tumor status (%)	
T2	62 (85.0)
T3	9 (12.3)
T4	2 (2.7)
N0	45 (61.6)
N1	28 (38.4)
TNM stage (%)	
IIa	41 (56.2)
IIb	21 (28.8)
IIIa	8 (10.9)
IIIb	3 (4.1)
Histology	
Ductal	52 (71.2%)
Lobular	14 (19.2%)
Mixed	5 (6.8%)
Medullary	1 (1.4%)
Mucinous	1 (1.4%)
Number of breast neoplasms	
1	60 (82.2%)
2	12 (16.4%)
3	1 (1.4%)
Additional nodes detected by MRI only	2* (2.8%)
Number of chemotherapy cycles administered	
3	54 (74.0%)
4	19 (26.0%)

* One additional node was fibroadenoma at FNA cytology.

residual cancer without the knowledge of the eventual pathologic results or clinical findings.

Pre- and post-chemotherapy MRI examinations were performed with a 0.5 T Philips Gyroscan NST MR unit (Philips Medical Systems, 5680 DA Best, The Netherlands), with the patient prone, using a bilateral multi-channel coil with the breast positioned in the wells. The sequences used were T1 weighted 3D-FFE, optimized to last less than 90 s and to cover the entire mammary gland and partially the axillary cavity with contiguous scans of 2.7–3 mm. More precisely, the following parameters were used: TR = minimum possible (23 ms); TE = 13.8 ms (in phase for 0.5 T unit); FA = 40°; partition = 40 (or up to 48); thickness of a single section 2.7–3 mm; FOV = 340; RFOV = 45–50%; matrix = 60%; direction of the heart beat artifact = foot-to-head; acquisition time = foot to head. Images acquired according

to a coronal plane were privileged to avoid flow artifacts originating from the heart and large blood vessels and to reduce times using a rectangular matrix. The same sequence was repeated before and, with no interval between repeats, five times 10 s after bolus injection of 0.1 mmol/kg of Gd-DTPA. Following acquisition, all the studies were processed by means of the following: (1) image subtraction: by subtracting the basal sequence of the other five, we tried to highlight even minimum enhancements, expected in vascularized areas such as those in neoplastic tissue; (2) the plotting of intensity/time curves, which show changes in enhancement intensity with time by means of a curve plotted on a system of Cartesian axes, with time on the X-axis and intensity on the Y-axis (the computer generates this graph after the positioning of a carefully selected Region of Interest in the same study area in each of the sequences obtained); (3) multi-planar reconstruction (MPR) of the anatomy of the breast; more precisely, the glandular body is reconstructed axially and longitudinally to allow a more accurate assessment of the site and size and a differential diagnosis with vascular structures. The persistence of neoplastic tissue by MRI was ascertained by checking the variation of the intensity–time curves following chemotherapy and the reduction in the enhancement peak.

All the diagnostic and treatment procedures were performed at the Azienda Ospedaliera Istituti Ospitalieri of Cremona, Italy. Response evaluated by either clinical palpation or MRI was assessed by the measurement of the changes in the product of the two largest diameters recorded at baseline and at the end of chemotherapy before surgery. According to the WHO criteria [17], tumor progression (PD) was defined as increase by at least 25%, stable disease (SD) as tumor size increase less than 25% or reduction less than or equal to 50%, partial response (PR) as tumor shrinkage greater than 50%, and CR as the complete disappearance of all clinical signs of disease. CR at MRI was defined as complete resolution of both tumor mass and enhancement. These criteria were decided prior to the study start. Surgery was planned after full clinical reassessment. Quadrantectomy or modified radical mastectomy was performed when indicated in association with full axillary dissection. All patients subjected to quadrantectomy underwent irradiation of the residual breast (60 Gys delivered in 6 weeks). The institutional review board approved this prospective study and signed informed consent was obtained from each patient.

Statistical analysis

Correlations between the tumor diameters as measured using clinical palpation and MRI techniques and comparison to the pathologic finding were made using Spearman's test for non-parametric data. All tests were two sided. P value < 0.05 was considered as significant. Statistica for windows software was employed for statistical computations.

Results

At baseline conditions, the majority of patients had only one malignant breast node. Multiple tumors were detected in 13 patients. In 11 cases additional nodules were detected by all the three techniques, while in two patients additional nodules were assessed by MRI only. All these nodules underwent fine needle aspiration. In the two cases in whom further nodules were detected by MRI and not by echography and mammography, cytology revealed breast cancer in one case and fibroadenoma in the remaining one (Table 1).

Tumor size evaluated by clinical examination showed a significant correlation with the size assessed by MRI either before treatment (Spearman $r = 0.61$, $p < 0.001$) or afterwards (Spearman $r = 0.54$, $p = 0.001$). The summary of response obtained by either MRI and clinical palpation is listed in Table 2. Disease response to treatment was more frequently observed with clinical palpation than MRI. At the end of treatment the primary tumor was not identifiable at clinical palpation in 20 patients and at MRI in 11. The concordance of the two methods was obtained in seven cases, whereas residual disease was detected by MRI in 13 cases judged as complete responders clinically and the opposite was found in four patients.

Post-chemotherapy histology evaluation revealed pathologic CR in three cases. Two of these cases were judged as complete responders by clinical palpation, one was considered as complete responder by MRI (Table 3). Residual disease consisted in *in situ* carcinoma without invasive disease in four cases, two of

Table 3. Clinical and MRI measurement in patients attaining pathological CR or residual *in situ* carcinoma at post-chemotherapy histology

Pathological examination	Maximum diameter (mm)	
	Clinical examination	MRI examination
No residual disease		
Case 1	20	7
Case 2	0	8
Case 3	0	7
Carcinoma <i>in situ</i>		
Case 5	10	12
Case 6	10	0
Case 7	0	10
Case 8	0	8

them were complete responders at clinical examination, one of them was complete responder at MRI. As outlined in Table 3, the maximum diameter of residual disease measured by MRI varied between 7 and 8 mm in pathological complete responders and between 8 and 12 mm in patients with *in situ* carcinoma.

All patients underwent definitive surgery (mastectomy or quadrantectomy) after PC. In the patient subset with multiple residual disease, conservative surgery was performed if the nodes were located within the same quadrant, whereas mastectomy was preferred in case of tumor location in different quadrant. Residual tumor assessed by the two techniques was correlated with the pathological measurements. In each patient, the longest diameter of the neoplastic residue assessed by clinical palpation or MRI was compared with the longest diameter of the infiltrating and *in situ* tumor observed in the gross specimen. Tumor dimension evaluated with MRI correlated better than clinical palpation with tumor diameter assessed by the pathologist (Figure 1). Post-chemotherapy residual tumor was also assessed by mammography and echography in 52 patients. Tumor size evaluated by the two techniques did not correlate with tumor size assessed either by pathology (Spearman $r = 0.19$ and 0.18 , respectively) or MRI (Spearman $r = 0.27$ and 0.28 , respectively).

Residual tumor size not identified by clinical palpation was less than 1 cm in 10 cases, between 1 and 2 cm in the remaining 10. The corresponding diameters not evaluated by MRI were found in six and five patients, respectively.

Table 2. Response rate to PC assessed clinically and at MRI

Response	Clinical examination (%)	MRI (%)
CR	20 (27.4)	11 (15.1)
PR	41 (56.2)	34 (46.6)
SD	12 (16.4)	28 (38.3)

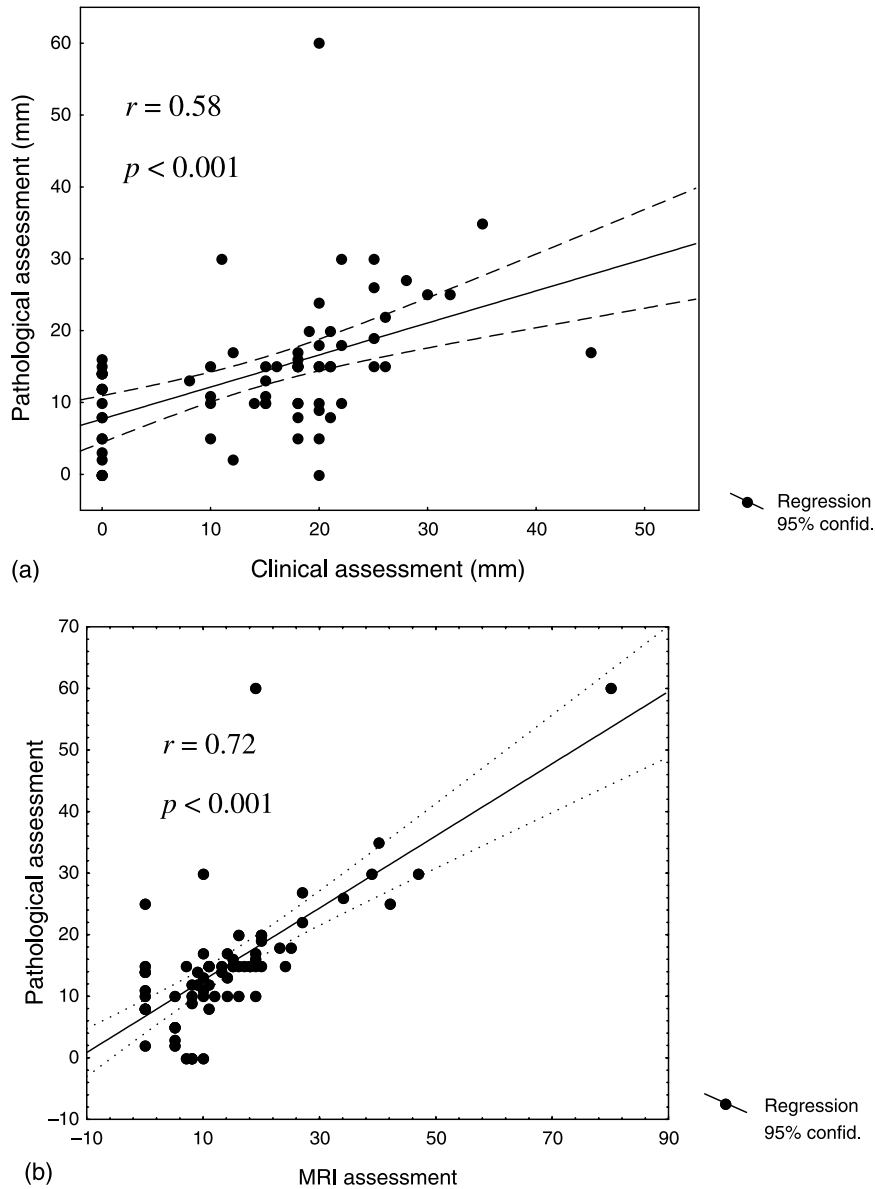


Figure 1. Relationship between residual tumor assessed at pathological examination and residual disease measured by clinical palpation (a) and MRI (b).

Discussion

In the majority of published trials, the response to PC in breast cancer patients has been assessed by physical examination [1, 2, 4, 7]. Although clinical response has been repeatedly found to correlate with patient outcome [2, 4], this technique is not to be considered as the gold standard. MRI, because of its ability to delineate anatomic detail of breast tumors, is a promising tool in this respect. Published series involving small numbers of patients [18–23] have shown that MRI is

more accurate than either echography and mammography or clinical palpation in evaluating the disease response to PC.

In our 73 breast cancer patients, uniformly treated with single agent epirubicin, CR was less frequently observed with MRI than with clinical examination, these data are in line to those previously published. On the whole, tumor size assessed by palpation significantly correlated with tumor size evaluated by MRI either at baseline conditions or at post-chemotherapy assessment. However, tumor diameters measured by

MRI after treatment better correlated than diameters obtained by clinical palpation with the diameters of surgically removed neoplasms. These data are consistent with a superiority of MRI over clinical palpation in the assessment of disease response to treatment. This is an interesting finding since in our experience echography and mammography have been found to be consistently less reliable than clinical examination in this clinical setting [12].

The majority of patients with clinical CR had residual MRI abnormalities, but also some patients with no residual enhancement at MRI had clinically detected tumors. Since none of the patients with pathological CR had CR by both MRI and clinical palpation, the combination of both techniques did not provide more stringent criterion of response.

It would be reasonable to determine if comparison of serial MRI exams could predict which patients would be likely to have good outcome, unfortunately the short follow-up of our cases enables us to correlate disease MRI response with disease free survival and overall survival.

The relationship between MRI and pathological diameters ($r = 0.72$) observed in the present study was lower than that observed in two published experiences involving 33 [22] and 18 [23] patients (0.90 and 0.93, respectively). The higher number of patients considered in the present series may have increased the tumor heterogeneity.

A non-invasive method able to quantify the amount of viable residual disease after PC would be helpful in planning optimal surgery or avoid unnecessary surgical approach, since residual invasive carcinoma or carcinoma *in situ* should be widely resected and the residual breast irradiated, while patients with pathological CR might be safely treated with radiotherapy alone. In this study, however, MRI did not predict pathological residual disease. MRI showed no significant residual enhancement at post-chemotherapy evaluation in 11 patients. Only one of them was a pathological responder, invasive carcinoma and *in situ* carcinoma were observed in nine and one patients, respectively. Residual tumors not detected by MRI was frequently represented by multiple small neoplastic foci (scattered in a larger parenchymal area) with maximum diameter beneath the maximum resolving power (2 mm) of the technique. By contrast, no viable tumor cells at pathological examination was observed in three patients, only one judged complete responder at MRI.

MRI also failed to detect females with an excellent response to chemotherapy in their invasive component. Among the four patients in whom *in situ* carcinoma was found at post-operative evaluation, in fact, three of them showed residual abnormal enhancement at MRI indistinguishable from that of invasive neoplasm and one showed no enhancement.

Low specificity is a very well recognized limitation of MRI in characterizing breast lesions [26]. This technique, in fact, is able to detect lesions as small as a few millimeters in size with an overall sensitivity reported in the range of 95–100%, by contrast the specificity was found to range between 37 and 97%, with false positive enhancement occurring frequently in benign breast lesions [26].

As mentioned in the introduction, lesions identification at MRI of the breast depends on contrast-enhancement within the breast after intravenous injection of contrast material. The detection of a malignant lesion within normal breast tissue is based on the earlier and stronger enhancement of malignant lesions as well as the morphologic features of the enhancing lesions [25, 26]. It is well known that chemotherapy may challenge the interpretation of breast MRI, since cell death, necrosis, and reduced vascular permeability may modify the enhancement characteristics of residual tumors [25]. In the present series, post-chemotherapy enhancement was often irregular and only in a few cases did the intensity–time curves show typical morphology. This altered enhancement was taken into account in the interpretation of post-chemotherapy breast MRI. In line with the literature [21], we considered ‘pathologic’ those curves which, though not showing the characteristic early peak, reached high intensity, equal to at least 70% of maximum intensity. These interpretation rules notwithstanding, we could not exclude that reduced MRI enhancement after chemotherapy administration may have conducted to an underestimation of the residual disease. On the other hand, it should be noted that all our patients underwent incisional biopsy at diagnosis and the enhancement of post-surgical granulation tissue could have lead to some false positive interpretations [25–27].

To conclude, on the basis of the results obtained in the present study and those published in literature, MRI appears to be a sensitive imaging technique modality for assessing the tumor shrinkage after PC in human breast cancer. MRI is able to represent the extent of cancer more accurately than clinical palpation

as compared to pathology specimens. It may aid in clinical management by helping to appropriately set patient's expectations about potential success or about the potential for breast conservation. Perhaps more importantly, the addition of this tool to our armamentarium could allow the physicians to provide documentation for extramural reviews in case of inclusion of patients in prospective clinical trials. Our data also points on the current limit of MRI. The technique is not capable of the distinction between residual fibrosis and viable tumor as well between carcinoma *in situ* and invasive disease. The introduction of positron emission tomography (PET) could add molecular or functional information to MRI and could overcome these limitations [28].

Acknowledgements

This study was supported in part by the Consiglio Nazionale Ricerche (CNR), Rome, Italy and by the Association: 'Amici dell'Ospedale di Cremona'.

References

1. Bonadonna G, Veronesi U, Brambilla C, Ferrari L, Luini A, Greco M, Bartoli C, Coopmans de Y, Zucali R, Rilke F, Andreola S, Silvestrini R, Di Fronzo G, Valagussa P: Primary chemotherapy to avoid mastectomy in tumors with diameter of three centimetres and more. *J Natl Cancer Inst* 82: 1539–1545, 1990
2. Fisher B, Bryant J, Wolmark N, Mamounas E, Brown A, Fisher ER, Wickerham DL, Begovic M, DeCillis A, Robidoux A, Margolese RG, Cruz Jr AB, Hoehn JL, Lees AW, Dimitrov NV, Bear HD: Effect of preoperative chemotherapy on the outcome of women with operable breast cancer. *J Clin Oncol* 16: 2672–2685, 1998
3. Mamounas EP, Fisher B: Preoperative (neoadjuvant) chemotherapy in patients with breast cancer. *Semin Oncol* 28: 389–399, 2001
4. Bonadonna G, Valagussa P, Brambilla C, Ferrari L, Moliterni A, Terenziani M, Zambetti M: Primary chemotherapy in operable breast cancer: eight years experience at the Milan Cancer Institute. *J Clin Oncol* 16: 93–100, 1998
5. Fisher B, Mamounas EP: Preoperative chemotherapy: a model for studying the biology and therapy of primary breast cancer. *J Clin Oncol* 13: 537–540, 1995
6. Aapro M: Neoadjuvant therapy in breast cancer: can we define its role? *Oncologist* 6(Suppl 3): 36–39, 2001
7. Bottini A, Berruti A, Bersiga A, Brizzi MP, Brunelli A, Gorzegno G, DiMarco B, Aguggini S, Bolsi G, Cirillo F, Filippini L, Betri E, Bertoli G, Alquati P, Dogliotti L: p53 but not bcl2 immunostaining is predictive of poor clinical complete response to primary chemotherapy in breast cancer patients. *Clin Cancer Res* 6: 2751–2758, 2000
8. Bottini A, Berruti A, Bersiga A, Brizzi MP, Bruzzi P, Aguggini S, Brunelli A, Bolsi G, Allevi G, Generali D, Betri E, Bertoli G, Alquati P, Dogliotti L: Relationship between tumor shrinkage and reduction in Ki67 expression after primary chemotherapy in human breast cancer. *Br J Cancer* 85: 1106–1112, 2001
9. Cocconi G, DiBlasio B, Alberti G, Bisagni G, Botti E, Peracchia G: Problems in evaluating response of primary breast cancer to systemic therapy. *Breast Cancer Res Treat* 4: 309–313, 1984
10. Jockelson M: Breast cancer imaging: the future. *Semin Oncol* 28: 221–228, 2001
11. Nistrom L: Breast cancer screening with mammography: overview of Swedish randomized trials. *Lancet* 341: 973–978, 1993
12. Fiorentino C, Berruti A, Bottini A, Bodini M, Brizzi MP, Brunelli A, Marini U, Allevi G, Aguggini S, Tira A, Alquati P, Olivetti L, Dogliotti L: Accuracy of mammography and echography versus clinical palpation in the assessment of response to primary chemotherapy in breast cancer patients with operable disease. *Breast Cancer Res Treat* 69: 143–151, 2001
13. Trecate G, Tess JD, Vergnaghi D, Bergonzi S, De Simone T, Mariani G, Musumeci R: Breast microcalcifications studied with 3D contrast enhanced high-field magnetic resonance imaging: more accuracy in the diagnosis of breast cancer. *Tumori* 88: 224–233, 2002
14. Stoutjesdijk MJ, Boetes C, Jager GJ, Beex L, Bult P, Hendriks JH, Laheij RJ, Massuger L, van Die LE, Wobbes T, Barentsz JO: Magnetic resonance imaging and mammography in women with a hereditary risk of breast cancer. *J Natl Cancer Inst* 93: 1095–1102, 2001
15. Khatri VP, Stuppino JJ, Espinosa MH, Pollack MS: Improved accuracy in differentiating malignant from benign mammographic abnormalities. *Cancer* 92: 471–178, 2001
16. Stomper PC, Winston JS, Herman S, Klippenstein DL, Arredondo MA, Blumenson LE: Angiogenesis and dynamic MR imaging gadolinium enhancement of malignant and benign lesions. *Breast Cancer Res Treat* 45: 39–46, 1997
17. Miller AB, Hoogstroten B, Staquet M, Winkler A: Reporting results of cancer treatment. *Cancer* 47: 207–214, 1981
18. Gilles R, Guinebretière JM, Troussaint C, Spielman M, Rietjens M, Petit JY, Contesso G, Masselot J, Vanel D: Locally advanced breast cancer: contrast-enhanced subtraction MR imaging of response to preoperative chemotherapy. *Radiology*, 191: 633–638, 1994
19. Abraham DC, Jones RC, Jones SE, Cheek JH, Peters GN, Knox SM, Grant MD, Hampe DW, Savino DA, Harms SE: Evaluation of neoadjuvant chemotherapeutic response of locally advanced breast cancer by magnetic resonance imaging. *Cancer* 78: 91–100, 1996
20. Rieber A, Zeitler H, Rosenthal H, Gorich J, Kreienberg R, Brambs HJ, Tomczak R: MRI of breast cancer: influence of chemotherapy on sensitivity. *Br J Radiol* 70: 234–239, 1997
21. Trecate G, Ceglia E, Stabile F, Tesoro-Tess JD, Mariani G, Zambetti M, Musumeci R: Locally advanced breast cancer treated with primary chemotherapy: comparison between magnetic resonance imaging and pathologic evaluation of residual disease. *Tumori* 85: 220–228, 1999
22. Esserman L, Kaplan E, Partridge S, Tripathy D, Rugo H, Park J, Hwang S, Kuere H, Sudilovsky D, Lu Y, Hylton N: MRI phenotype is associated with response to doxorubicin and cyclophosphamide neoadjuvant chemotherapy in stage III breast cancer. *Ann Surg Oncol* 8: 549–559, 2001

23. Weatherall PT, Evans GF, Metzger G, Saborrian MH, Leitch AM: MRI vs histologic measurement of breast cancer following chemotherapy: comparison with x-ray mammography and palpation. *J Magn Reson Imaging* 13: 868–875, 2001
24. Davis PL, Staiger MJ, Harris KB, Ganott MA, Klementaviciene J, McCarty Jr KS, Tobon H: Breast cancer measurements with magnetic resonance imaging, ultrasonography, and mammography. *Breast Cancer Res Treat* 37: 1–9, 1996
25. Kinkel K, Hylton NM: Challenges to interpretation of breast MRI. *J Magn Reson Imaging* 13: 821–829, 2001
26. Esserman L, Wolverton D, Hylton N: Magnetic resonance imaging for primary breast cancer management: current role and new applications. *Endocrine-Related Cancer* 9: 141–153, 2002
27. Frei KA, Kinkel K, Bonel HM, Lu Y, Esserman LJ, Hylton NM: MR imaging of the breast in patients with positive margins after lumpectomy: influence of the time interval between lumpectomy and MRI imaging. *Am J Roentgenol* 175: 1577–1584, 2000
28. Mankoff DA, Dunnwald LK, Gralow JR, Ellis GK, Charlop A, Lawton TJ, Schubert EK, Tseng J, Livingston RB: Blood flow and metabolism in locally advanced breast cancer: relationship to response to therapy. *J Nucl Med* 43: 500–509, 2002

Address for offprints and correspondence: Prof Luigi Dogliotti, Oncologia Medica, Azienda Ospedaliera San Luigi, Regione Gonzole 10, 10043 Orbassano, Italy; *Tel.:* +39-11-9026511; *Fax:* +39-11-9026676; *E-mail:* luigi.dogliotti@unito.it